Percutaneous Varicocele Embolization – Minimally Invasive Treatment of Male Infertility

Radiology Department, Coimbra University Hospitals

Head of Department: Prof. Dr. Filipe Caseiro Alves

Rodrigues, Lara[1]; Ramos, Ana Beatriz[2]; Eufrásio, Pedro[3]; Gil Agostinho, Alfredo[1]; Donato, Paulo[1]; Carvalheiro, Vítor[1]; Caseiro-Alves, Filipe[1]

1 – Radiology Department, Coimbra University Hospitals; 2 – Radiology Department, Porto Hospital; 3 – Urology and renal Transplantation department, Coimbr University Hospitals

Objectives:

Brief review on the subject percutaneous embolization of varicocele grade II to IV, with illustration of the technique, enumeration and analysis of the possible complications of the therapeutic effects obtained.

Methods:

The authors retrospectively analyzed 50 infertile men with a mean age of 34.78 (± 4.37) years, underwent percutaneous embolization of the spermatic vein by clinically detectable varicoceles between January 2009 and October 2010, at University Hospitals of Coimbra. Were evaluated for semen quality, according to WHO criteria (WHO, 2010). Seminal analysis was performed before embolization and repeated 4-6 months after the procedure. Was considered to obtain a positive effect when the semen parameters changed from abnormal to normal according to WHO criteria (reference values: total sperm count ≥ 39 million sperm / ejaculate, sperm concentration ≥ 15 million sperm / mL, ≥ 50% progressive mobility, morphology ≥ 4% normal forms).

Results and Discussion:

Varicoceles consist of varicose dilation pampiniform plexus and spermatic vein, may present with pain, testicular atrophy and male infertility. Affecting 15% of men, being present in 40% of the infertile male population. Usually unilateral and more frequent on the left, may be bilateral (9%) or present on the right (1-2%). They have indicated to treat symptomatic varicoceles, testicular atrophy with adolescents and adults with multiple alterations in infertile semen. Through the clinical evaluation and semen analysis, the good results of percutaneous embolization of the spermatic vein are demonstrated in terms of efficacy and safety. The main limitations of this procedure consist in the impossibility of catheterization of the spermatic vein (anatomical variants, vasospasm and intimal dissection), the possible migration of coils and the use of ionizing radiation and iodinated contrast product.

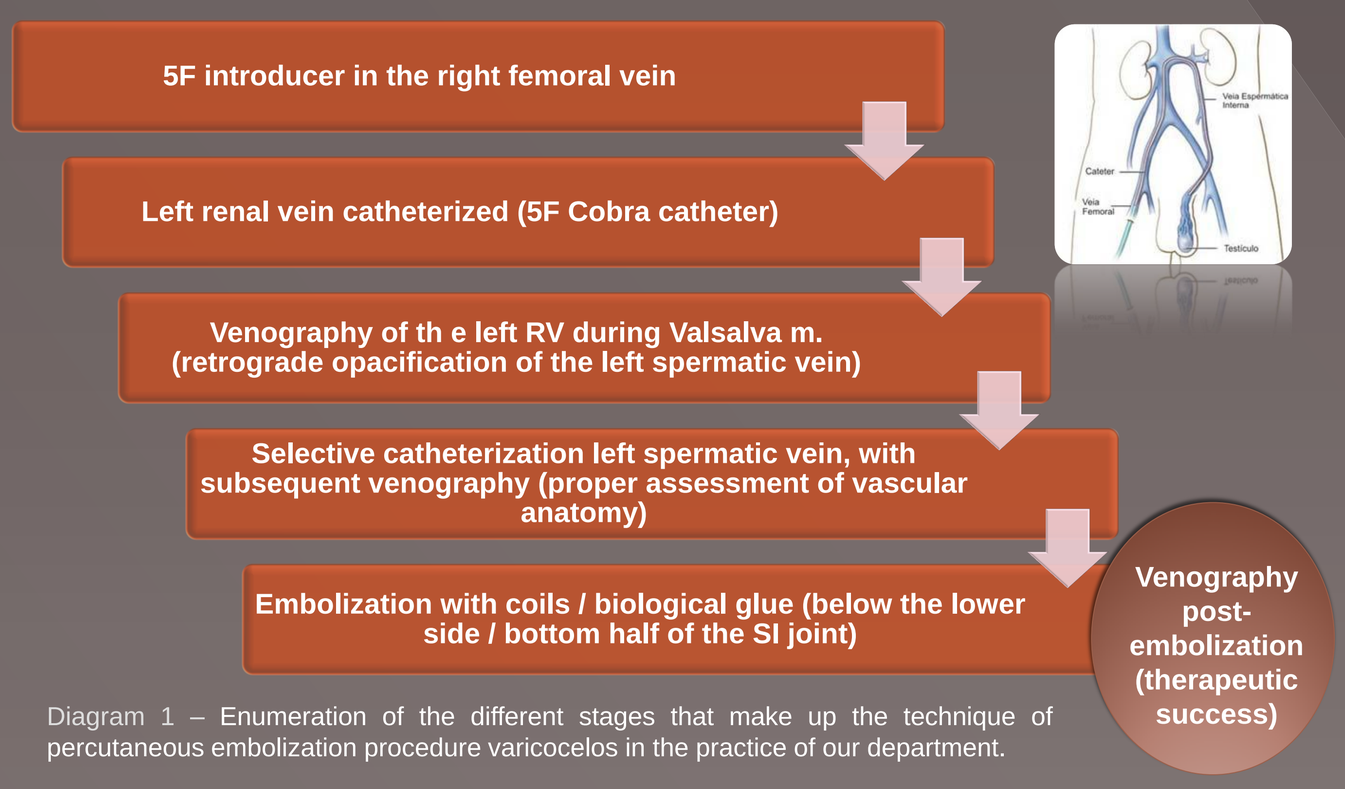

Diagram 1 – Enumeration of the different stages that make up the technique of percutaneous embolization procedure varicocelos in the practice of our department.

Figure 1 - (a, c) digital subtraction angiographic images showing selective catheterization of the left spermatic vein and opacification of large varicocele on the same side. (b, d) Images without angiographic and digital subtraction, respectively showing the post-implantation of coils along the path of the spermatic veins, with an effective reduction / termination of their flow.

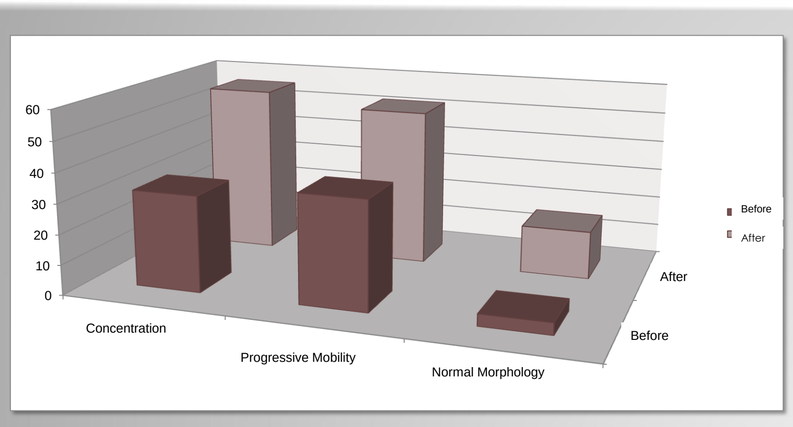

After the spermatic vein embolization, a significant improvement of semen parameters, particularly the concentration and morphology of sperm mobility (p = 0 002, p = 0.067, p = 0.074 respectively).

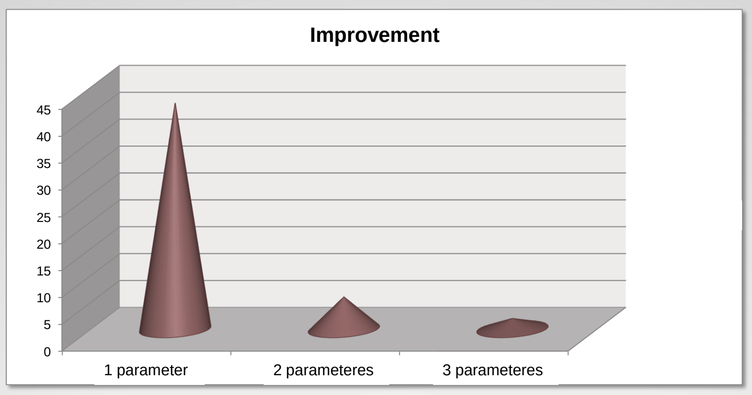

It was observed that the procedure induced a significant improvement in a parameter in 42 subjects, two parameters for six subjects in the study group and on three parameters (concentration, mobility and morphology) to two of the patients.

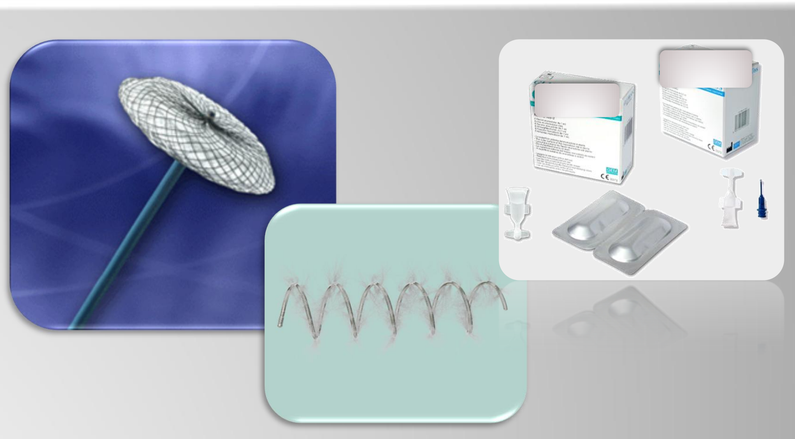

Figure 2 - Main angiographic instruments used in percutaneous embolization of the spermatic vein; Amplatzer, coil and biological glue (from left to right).

Conclusions:

The spermatic vein embolization improves semen quality in infertile population, including the parameters of concentration, sperm mobility and morphology. It is a technique of minimally invasive Interventional radiology without the need for general anesthesia or stitches / scars, providing a rapid recovery of the patient, with a short hospital stay and proven therapeutic results.